



SOPRUCARE

THE REVELATION

Clinical booklet



SOPRO CARE

Acknowledgements

This clinical booklet was written with the support and the guidance of Dr. H-C. Hollay (D.D.S., Implantologist - private practice, Munich, Germany), Dr. J. Launais (D.D.S., private practice, Marseilles, France), Pr. F. Louise (DDS, Head and professor, Department of Periodontics - Dental School, Aix-Marseilles University, Marseilles, France), Dr. M. Pisapia (D.D.S., past-Assistant Professor, North Hospital, Aix-Marseilles University, France - private practice dedicated to General and Paediatric Dentistry), Pr. H. Tassery (DDS, MSc., PhD., Professor, head of the Preventive and Restorative Department - Marseilles Dental School, Aix-Marseilles University, Marseilles, France), Dr. F. Vidot (D.D.S. Assistant-Professor, Department of Periodontics - Dental School, Aix-Marseilles University, Marseilles, France), and the research team involved in this project and with the support of scientific consultants.

SOPRO's experience in the field of intra-oral video has been greatly enriched by input from dentists who, through their professionalism, have contributed to the development of new concepts.

But our special thanks go also to each SOPRO user who shows trust in us, each time they choose one of our products.

Dr. Pierre Montillot
PhD., C.E.O. SOPRO ACTEON GROUP

CONTENT

Product Summary.....	6
Introduction.....	6
TECHNOLOGY.....	9
1.1 Patented technology.....	10
1.2 Phenomenon of fluorescence.....	10
1.3 SOPROCARE concept.....	12
CLINICAL.....	15
2.1 Dental plaque.....	16
2.2 Gingival inflammation.....	17
2.3 Carious lesions.....	19
PRODUCT MAKE-UP.....	23
Camera and its accessories.....	24
DECISION MAKING DIAGRAMS.....	27
Clinical case n°1.....	28
Clinical case n°2.....	28
Clinical case n°3.....	29
Clinical case n°4.....	29
Clinical case n°5.....	30
Clinical case n°6.....	30
Clinical case n°7.....	32
Clinical case n°8.....	32
Clinical case n°9.....	33
Clinical case n°10.....	33
Clinical case n°11.....	34
Clinical case n°12.....	34
Clinical case n°13.....	35
Clinical case n°14.....	36

SOPROCARE

Product Summary

— A unique view

An anatomical view of the tooth in a native fluorescence image allows the viewer to assess the condition of the tissues being observed:

- Up to 100 x image magnification.
- Selective chromatic amplification of the endogenous fluorescence alone, which is reproducible and does not require any pseudo colour processing software.
- Unrivalled resolution in fluorescence imaging.

— A prophylactic tool

SOPROCARE is an effective, multi-purpose device for tissue differentiation in real time, which is dedicated to speeding up dentists' daily diagnostic procedures and early detection of disease symptoms in order to preserve dental structures.

— A communication aid

Improving the oral and dental health of patients relies on the quality of the two-way relationship between dental practitioner and patient. The information gathered by SOPROCARE will enable the treatment team to communicate about the patient's individual state of oral health. The first signs of pathology are demonstrated to the patient, the probable progress can be illustrated and the therapeutic measures, to halt the disease, can be explained. The visual follow-up can motivate patients over time.

This tool is an addition to the range of preventive techniques that enable us to set up the most suitable treatment for each patient.



Introduction

In the diagnostic process of general practice, the clinical examination is based on visual information and tactile sensation obtained with the aid of mirror and probe. But this method has quite limited performance and may even prove traumatic.

Non-invasive diagnostic aids have appeared in recent years. These devices rely on the principles of transillumination, laser and differential quantitative measurement of fluorescence or electrical impedance. However, their limited field of investigation and constraints on their use make them difficult to integrate into the daily dental practice.

Full realization of the needs in oral prophylaxis combined with the historical expertise of SOPRO in dental imaging and fluorescent technology made it possible to develop SOPROCARE, the new fluorescent imaging system combined with selective chromatic amplification.

SOPROCARE is intended for clinical practice in general dentistry, directed towards preventive concepts, prophylactic care and overall patient management. Its purpose is to tell you about the condition of the tissues on which you are working.


In its three operating modes (PERIO, CARIO, DAYLIGHT) the system is used live because it does not emit ultraviolet or ionising radiation.

The PERIO mode informs practitioners about the presence of dental plaque while simultaneously enabling them to distinguish healthy from diseased gingival tissues.

In CARIO mode, the camera can be used to observe and show patients a warning sign of enamel and dentinal caries. The other healthy tissues are represented in black and white.

In DAYLIGHT mode, the Macrovision makes visible the imperceptible and allows watching the stability of micro lesions and their evolution.

This booklet guides practitioners through the discovery of a new approach to communicating with and motivating patients, illustrated through a number of clinical cases.





SOPRUCARE



TECHNOLOGY

1.1 PATENTED TECHNOLOGY

In the core business of SOPRO, the intraoral video combines several areas of expertise: optics, electronics and signal processing as well as micromechanics.

A scene illuminated by optical methods such as LEDs is captured by an image sensor (CCD), electronically processed by specific circuits and directed to imaging or storage devices.

Fluorescence imaging for diagnostic purposes requires a very high image quality. Technology developed by SOPRO in order to achieve this high quality level was the subject of major research work and accompanied by the registration of numerous international patents.

This technology uses native autofluorescence and avoids resorting to software interfaces involving the use of pseudo colours which are subject to approximate interpretation.

1.2 PHENOMENON OF FLUORESCENCE

Fluorescence is light emission produced when molecules present in a classically ground state (solid or liquid) are illuminated by a light source within the UV spectrum (<400 nm) or the visible spectrum (>400 nm). It should be noted that humans see visible light over a spectral band ranging from 400 nm to 700 nm wavelength.

Principle of autofluorescence

Certain molecules in the body emit a fluorescence without external intervention other than light excitation. This is known as autofluorescence or endogenous fluorescence, to distinguish it from induced or exogenous fluorescence which uses external fluorophores that can be administered systemically or topically.

This is the phenomenon of autofluorescence which is used by SOPROCARE. It is based on the stimulation of endogenous fluorophores present in the tissues of the teeth.

This non-invasive imaging can thus be performed without any risk and does not require any exogenous fluorophore, which can sometimes prove toxic and necessitate specific regulation.

Principle of the PERIO mode

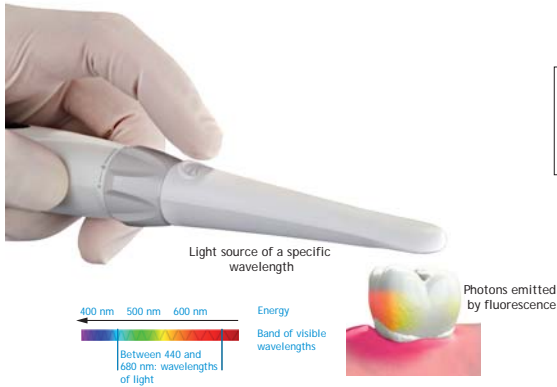


Figure 1:
Operating principle
of the SOPROCARE
in PERIO mode

The PERIO mode also uses the phenomenon of fluorescence but this time combined with selective chromatic amplification.

When this mode is in use, the tooth is illuminated with both blue LEDs (for fluorescence) and white LEDs (to maintain the relief) in order to recover the fluorescence emitted in return by pigments present in dental plaque.

To highlight gingival inflammations, SOPROCARE uses the settings of selective chromatic amplification to enhance this pathology.

Principle of the CARIO mode

The principle illustrated by the following diagram can be broken down into the following stages:

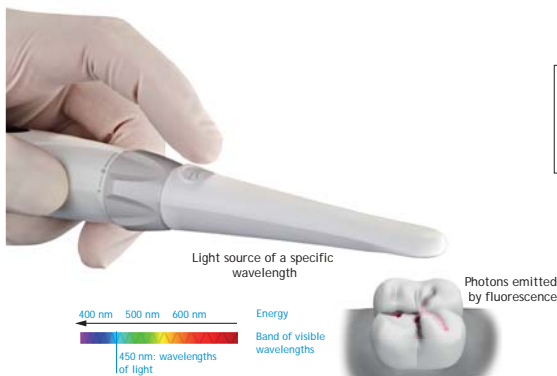

Figure 2:
Operating principle
of the SOPROCARE
in CARIO mode

- The photons (elementary light particles) supplied by an external light source such as a laser or a lamp (with a narrow wavelength bandwidth) shine onto the material(s) of the tooth (enamel and dentine).

- The energy supplied by the excitation source (LEDs camera) to the material (dentine) causes an increase in the energy of the elementary particles of the material which become highly unstable.
- In order to return to a ground state, they release their excess energy by emitting photons of lower energy than the excitation light and a higher wavelength (Stokes Law). This is the phenomenon of fluorescence.

1.3 SOPROCARE CONCEPT

Dental prophylaxis aims to prevent and therefore stop the appearance or spread of a disease. Its universal principle nowadays is to avoid damage by the early detection of pathological symptoms and minimally invasive restoration while treating the cause.

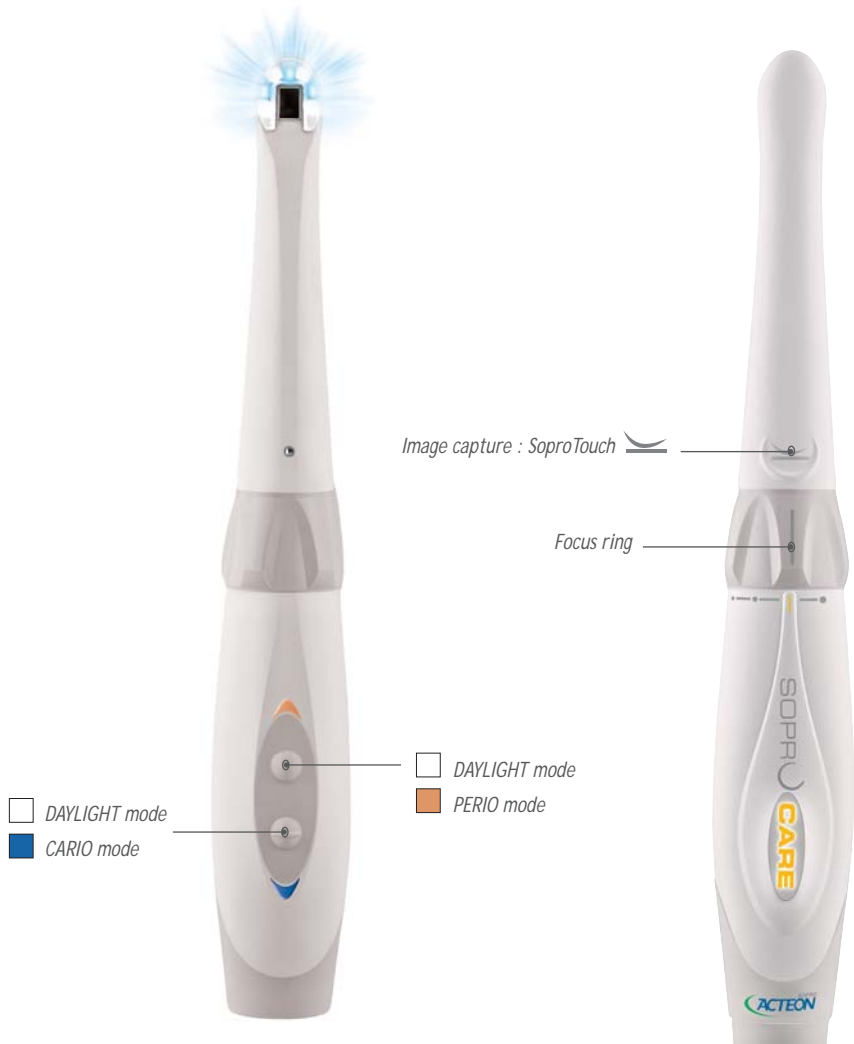It starts first of all with the patient's realization of the importance of his cooperation in maintaining his health. A patient who is aware of his oral and dental health will thus be more likely to grasp and accept the necessary treatment plan that is set up.

The general concept of prophylaxis therefore hinges on communication with the patient in order to motivate and educate him about his oral hygiene.

Prophylaxis begins with a complete periodontal and caries check-up. To assist dentist and/or hygienist in their preventive care and visual diagnosis, SOPROCARE offers three distinct operating modes:

- In PERIO mode (represented by a yellow square on the image), SOPROCARE helps the practitioner to visualise the presence of dental plaque but also reveals gingival inflammations alongside this deposit.
- In CARIO mode (represented by a blue square on the image), SOPROCARE alerts the practitioner to the presence of enamo-dentinal caries especially on the occlusal surface of the teeth.
- In DAYLIGHT mode (represented by a white square on the image), the camera allows the user to magnify anatomical details that are invisible to the naked eye even with a mirror.

Figure 3:
Three operating modes of SOPROCARE







SOPRUCARE

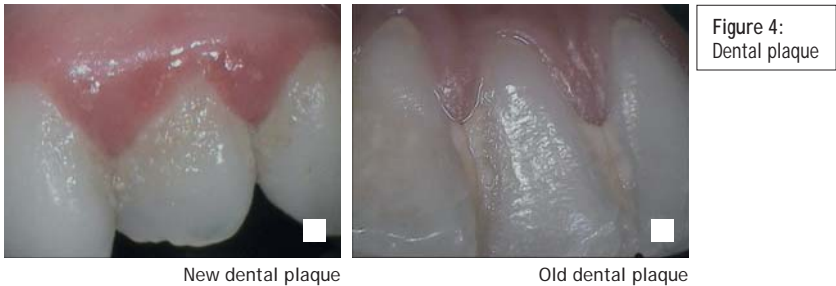

CLINICAL

2.1 DENTAL PLAQUE

Definition

Dental plaque is a soft and thin biofilm of food debris, mucin and dead epithelial cells deposited on the teeth, providing the medium for the growth of various bacteria. Plaque plays an important role in the development of dental caries and periodontal and gingival diseases and provides the base for the development of calcified plaque which forms dental calculus.



New plaque may then be compared to a milky and/or grainy layer that adheres to the tooth and can easily be removed by the use of a toothbrush.

Old plaque, on the other hand, presents a rough surface and can only be removed by mechanical action such as that of piezo-ultrasonic scaling.

Methods for detecting these deposits

1 - Clinical inspection

The aim of visual diagnosis is to inspect all the surfaces (labial, buccal, interproximal, lingual or palatal) of a tooth in order to detect any plaque that may be present.

Even under the best conditions (use of a mirror, good lighting by shadowless lamp, etc.), visual inspection is still difficult to perform, especially for posterior sites, and it generally requires the use of a probe to scratch the tooth surface and thereby pick up deposits if any are present.

2 - Plaque disclosing solution

The plaque disclosing solution consists of a mouthwash containing a dye in liquid or tablet form that reacts on contact with deposits and thus reveals the places where dental plaque persists after cleaning. This means the patient's brushing technique can be corrected because it reveals the areas that are forgotten or neglected.

However, this solution takes a long time to apply and therefore increases the consultation time. The resulting staining can sometimes be embarrassing for the patient and, after use of the plaque disclosing solution, the dentist has to carry out prophylactic cleaning in order to get rid of the discoloration. Furthermore, the results are dependent on application of the plaque disclosing solution. There is also a possibility of certain allergies and an unpleasant taste.

3 - Less time lost

Finally, SOPROCARE combines all advantages of these two main methods without their disadvantages.

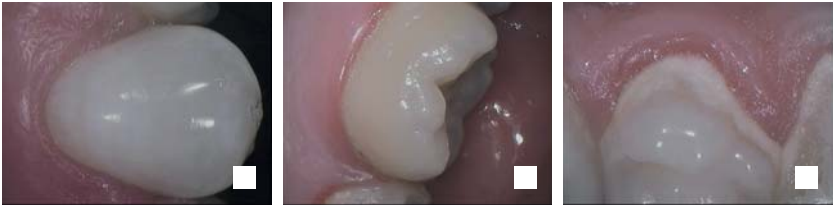SOPROCARE enhances the visual inspection in DAYLIGHT mode and reveals the same information as the disclosing solutions in PERIO mode.

2.2 GINGIVAL INFLAMMATION

Definition

Since the bacteria present in dental plaque are foreign bodies, they represent an attack and trigger a defensive reaction from the gum. This reaction takes the form of visible inflammation due to the influx of blood induced in order to bring the immune defensive cells to the site of the attack.

Figure 5: Gum



Healthy gum Thin gingival inflammation Severe gingival inflammation

Healthy gum has a pale pink color, “an orange peel” texture and does not bleed on contact with the probe.

In the case of inflammation, the gum becomes red, smooth and swollen even if all these symptoms are not necessarily present simultaneously during this disease. The inflamed gingiva bleeds readily, either during brushing, during use of the probe or sometimes even spontaneously.

Changes in colour, consistency, texture, volume and contour of the gum will therefore be observed.

— Methods for diagnosing gingival inflammation

1 - Clinical inspection

The aim of visual diagnosis is to assess the four cardinal signs of inflammation: redness, edema, heat and pain.

Even under the best conditions (use of mirror, lighting by shadowless lamp, etc.), visual inspection is still difficult to carry out, especially for the posterior teeth.

2 - Gingival bleeding

Gingival bleeding is regarded as a revelatory sign of gingival inflammation, which is extremely early and far more precise than redness of the tissues. However, no conclusions about the progress of the disease can be drawn from an absence of bleeding and there may still be inflammation without necessarily causing any bleeding.

The bleeding can be assessed by the use of a probe, a painful instrument for the patient and not very reliable from one site to another because it is dependent on the pressure exerted at each site, which varies from one practitioner to another.

3 - Biological and bacterial tests

There are biological and bacterial tests that can be used to confirm the presence of gingival inflammation while analysing the bacterial flora present at the site. However, these tests are very expensive and lengthy to set up in practice (collecting samples from inflamed sites and healthy sites, followed by laboratory analyses).

4 - Less time lost

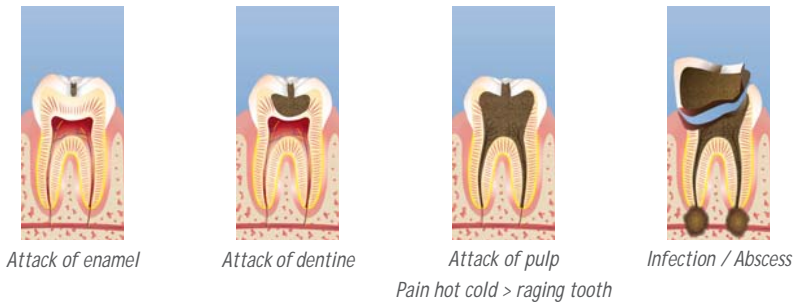
Finally, SOPROCARE in PERIO mode effectively highlights gingival inflammation due to these deposits and limits the practice of probing thanks to its ease of use.

2.3 CARIOUS LESIONS

Definition

Dental caries is a localized process of bacterial origin which leads to demineralization of the hard dental tissues. It affects the enamel, dentine and cementum to varying degrees. As the caries advances, a cavity will force a path towards the interior of the tooth until it reaches the pulp. If no intervention takes place, the carious lesion may lead to total destruction of the tooth.

Figure 6: Progression of caries



The tooth's defensive mechanisms, directly linked to odontoblasts which are cells responsible for the production of dentine, are triggered when an external attack is perceived. These cells are found directly at the interface between the pulp and dentine. Their extension to inside the dentinal tubules makes them extremely sensitive in terms of detecting attack. They react in a more or less orderly way when an acid front appears beyond the barrier formed by the enamel, or when bacteria penetrate as far as the dentine and launch the process of destruction of mineralised tissues.

Once the carious process is highly active, dramatic progression of a carious lesion does not leave the odontoblasts enough time to produce sclerotic dentine with the purpose of isolating the pulp from the carious process. However, reparative dentine or atubular fibrodentine is synthesized.

When the carious process is slower, the odontoblasts manage to produce this sclerotic, intratubular and peripulpal dentine.

Methods for diagnosing carious lesion

1 - Caries risk

The risk of caries is defined by a whole set of criteria together with the environment and the patient's physiology (dietary habits, hygiene, oral flora, salivary pH, socio-economic status, etc.). Assessment of the risk is the first step in the diagnosis process.

2 - Clinical inspection

The aim of visual diagnosis is to detect any opacity, staining or change of translucency with or without drying.

On clean teeth and under good lighting, the use of a mirror and appropriate magnification aids, will optimize the visual inspection. But it does not prevent the diagnosis from remaining subjective, constrained by difficult access to certain areas and the lack of lighting in the posterior areas.

It should be added that the morphology and discolorations that may be observed in the fissures are not automatically signs of caries.

3 - Probing

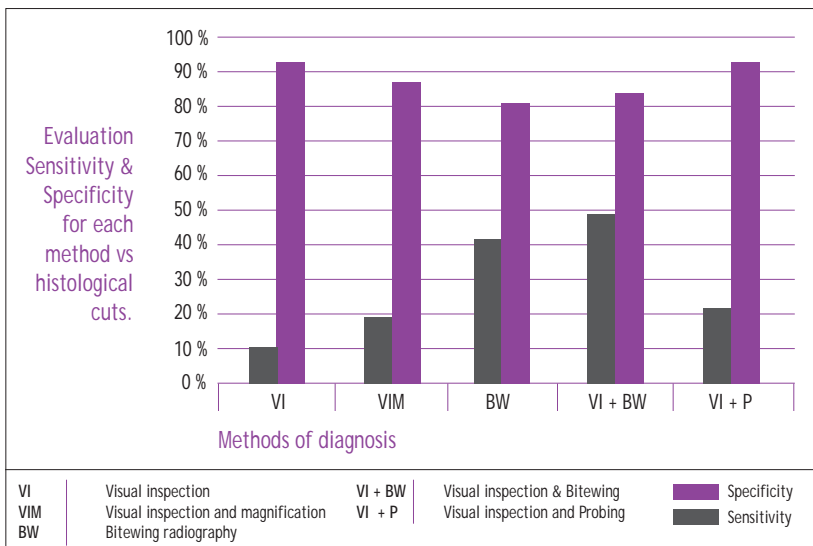
Dependent on the geometric characteristics of the probe and the fissure anatomy, this method does not provide a reliable indication of the presence of a lesion in the area being examined.

Furthermore, probing may prove traumatic in an area of enamel that has an intact surface but a weakened subsurface.

In addition, probing can also play a part in transporting bacteria from one site to another.

4 - Conventional radiograph

Enamel and dentine are masses with a high density. This is why occlusally a conventional X-ray offers poor sensitivity for enamel lesions (45% alone and 49% in combination with visual inspection), as shown in the study conducted by Lussi in 1993 regarding methods for detecting fissure caries without macroscopic cavitation. By contrast, the specificity of conventional radiographs remains quite high (83% to 90% in combination with visual inspection).



Comparison of the precision of different methods for diagnosing fissure caries

Interproximally, radiography is currently the most effective diagnostic tool for detecting enamel or dentine damage on bitewing films. Its sensitivity is between 71% and 100%. It depends on the location of the suspected lesion (interproximal, labial, buccal, palatal or lingual). Its specificity is between 99% and 100%.

It should also be remembered that radiographs greatly underestimate the size of lesions in terms of depth and stage of progression.

5 - Optimization of the caries diagnosis

Finally diagnosing carious lesions on occlusal surfaces is a challenge for the dentist and, in the absence of cavitation, the performance of the three above-mentioned methods is generally not good enough. In any case, visual inspection with the aid of an intraoral camera would improve decision-making and provide better guidance on treatment choices.

Moreover, if the camera offers an occlusal caries detection mode which uses the well-trieed fluorescence technology, the diagnosis made by the practitioner would be more accurate.





SOPRUCARE



PRODUCT MAKE UP

— SOPROCARE and its accessories



1 Handpiece

2 SoproTips




3 Handpiece holder



4 Docking station







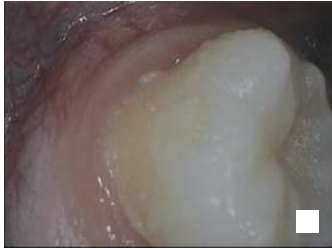SOPRUCARE



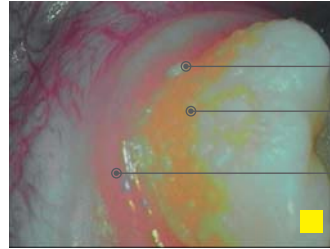
DECISION MAKING DIAGRAM

Over the following cases, the clinical situations most commonly encountered when performing prophylaxis are explained in order to show that SOPROCARE helps dentists to position themselves in the “ideal therapeutic gradient” (concept of Tirlet and Attal).

Clinical case n° 1



DAYLIGHT mode



PERIO mode

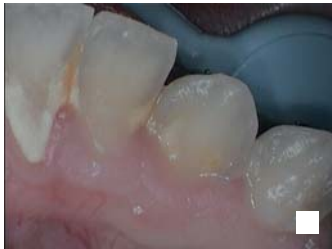White and grainy:
new dental plaque

Orange and yellow:
old dental plaque

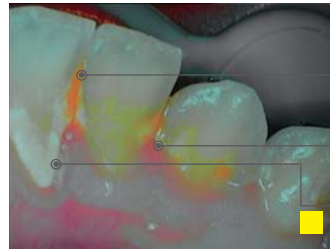
Magenta pink border:
slight gingival inflammation

Treatment decision: prophylactic cleaning of the site and hygiene advice.

Clinical case n° 2



DAYLIGHT mode



PERIO mode

Orange and yellow:
old dental plaque

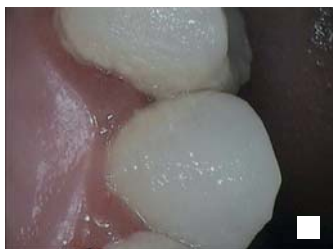Magenta pink border:
slight gingival inflammation

White and milky:
New dental plaque

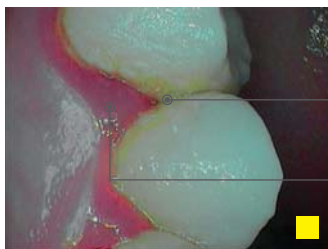The patient's age and dietary habits (tea, coffee, smoking, etc.), is indicated by the coloring of the old and new dental plaque but may differ from one patient to another and also from one country to another.

Treatment decision: scaling of the site and hygiene advice.

Clinical case n° 3



DAYLIGHT mode



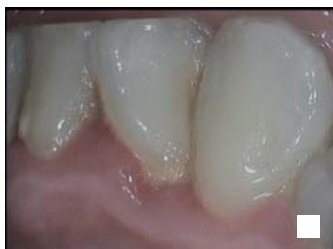Orange: old dental plaque

Papillae and magenta red border:
severe gingival inflammation

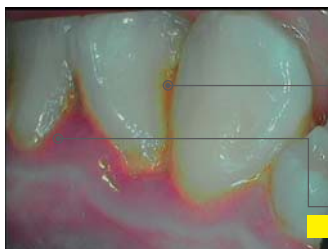
PERIO mode

Treatment decision: scaling of the site and hygiene advice.

Clinical case n° 4



DAYLIGHT mode



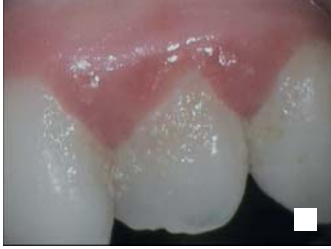Orange: old plaque in
interproximal space and
at the neck of the teeth

Papillae and magenta red border:
severe gingival inflammation

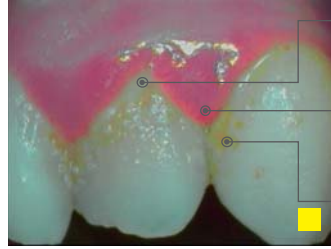
PERIO mode

Treatment decision: scaling of the site and hygiene advice.

Clinical case n° 5



DAYLIGHT mode



PERIO mode

White and milky:
new dental plaque

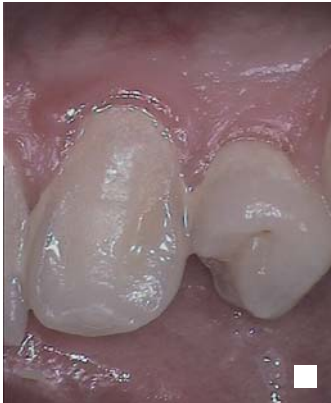Papillae and magenta
red border: severe
gingival inflammation

Orange: old dental plaque

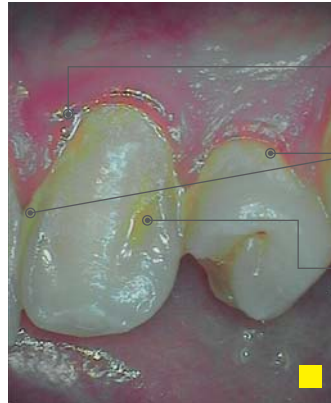
Treatment decision: scaling of the site and hygiene advice.

Clinical case n° 6

Initial situation



DAYLIGHT mode

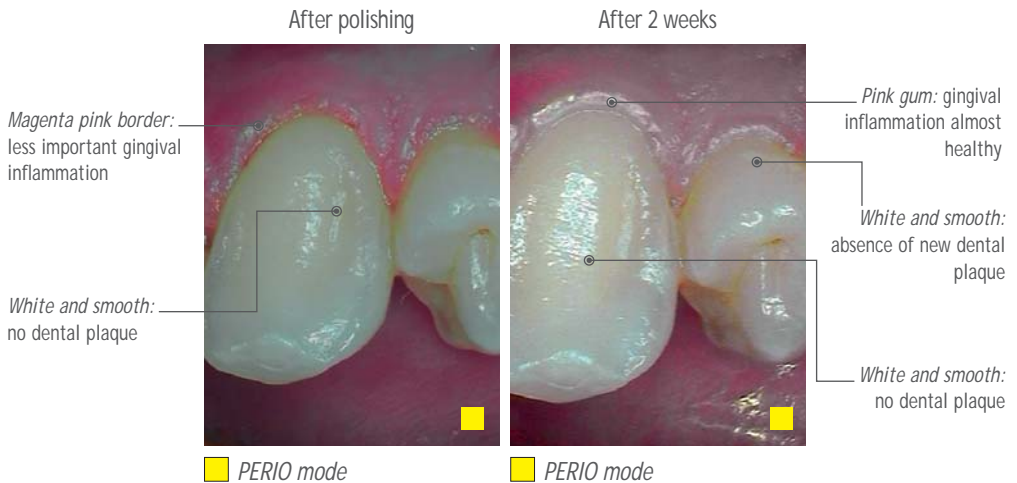
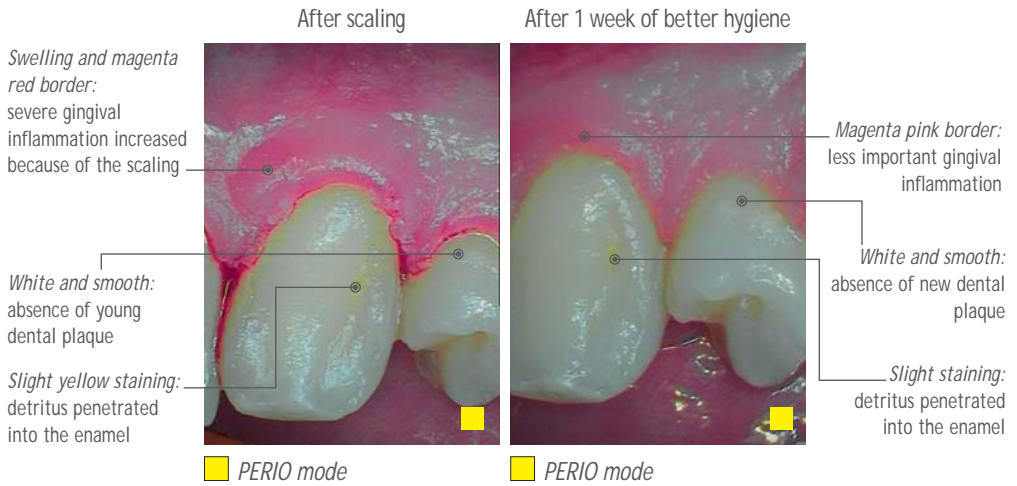


PERIO mode

Swelling and magenta
red border:
severe gingival inflammation

White and milky:
new dental plaque

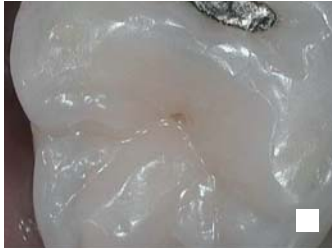Orange: old dental plaque



In this complete case, the regression of severe gingival inflammation can be observed. The efficiency of prophylactic treatments can be appreciated.

A slight yellow color can persist after cleaning because food pigments contained in the deposits have penetrated into enamel.

Clinical case n° 7



DAYLIGHT mode

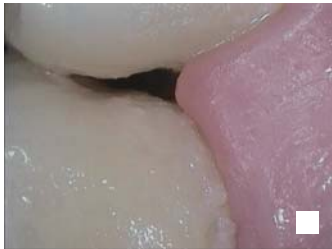

Red signal in fissure:
warning of a groove caries

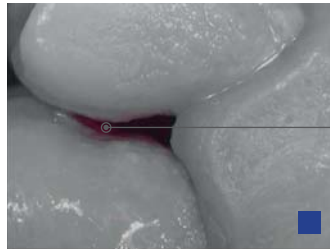
CARIO mode

If there is a warning signal, professional prophylactic cleaning must always be carried out, in order to confirm or not the caries.

Clinical case n° 8



DAYLIGHT mode

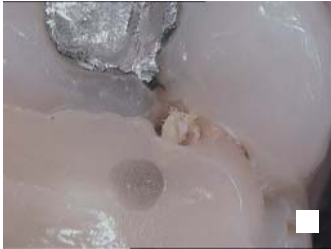

Red signal in
proximal surface:
warning of proximal caries


CARIO mode

If there is a proximal signal, X-ray must always be carried out to confirm the lesion.

Clinical case n°9



DAYLIGHT mode

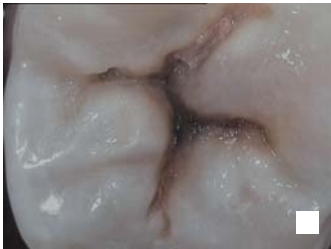

Red signal in fissure:
warning of recurring caries

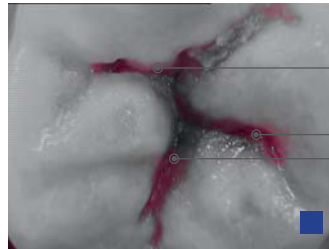
CARIO mode

If there is a warning signal, professional prophylactic cleaning must always be carried out, in order to confirm or not the caries.

Clinical case n°10



DAYLIGHT mode



Red signal in the
grooves: warning of
grooves caries

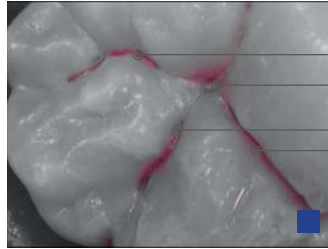
CARIO mode

If there is a warning signal, professional prophylactic cleaning must always be carried out, in order to confirm or not the caries.

Clinical case n° 11



DAYLIGHT mode

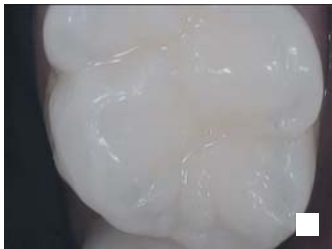

CARIO mode

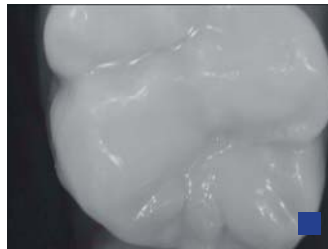Red signal
in the grooves:
warning of grooves caries
which is not visible in
DAYLIGHT mode

In this case, it is after a prophylactic cleaning, the dentist was diagnosed a caries. This lesion is not diagnosable with a visual examination even with a magnification.

Clinical case n° 12



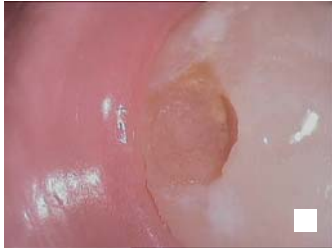DAYLIGHT mode



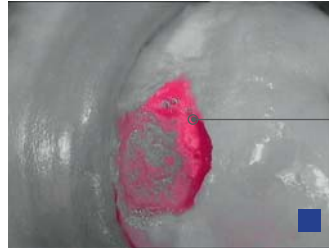
CARIO mode

No signal: the healthy
tissues are completely
in black and white

Clinical case n° 13




DAYLIGHT mode



CARIO mode

*Red signal in cavity:
warning confirms the
enamo-dentinal caries*

If there is a warning signal, professional prophylactic cleaning must always be carried out.



CARIO mode

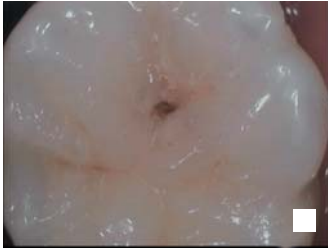

CARIO mode

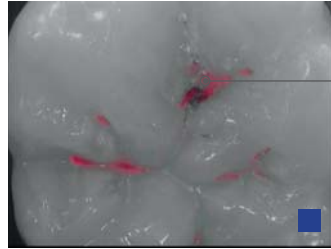
*There is no red tissue at
the end of the excavation*

*The infected
dentine in red
is removing*

Clinical case n° 14

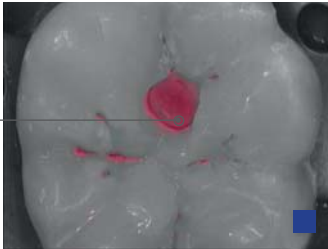


□ DAYLIGHT mode

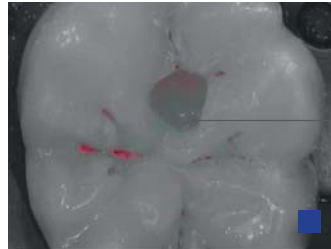


■ CARIO mode

Red signal in fissure:
warning of a groove caries



■ CARIO mode




■ CARIO mode

There is no red tissue at
the end of the excavation

During the
treatment

Dotted lines for handwriting practice, consisting of 20 horizontal rows across the page.





PUBLICIS ACTIV - RCS Paris B 337 924 483



Non contractual document - Ref. 011540D / D76151 - Copyright© 2014 SOPRO. All rights reserved.
No information or part of this document may be reproduced or transmitted in any form without the prior permission of SOPRO.

