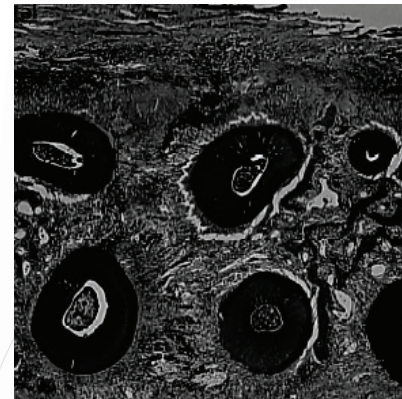
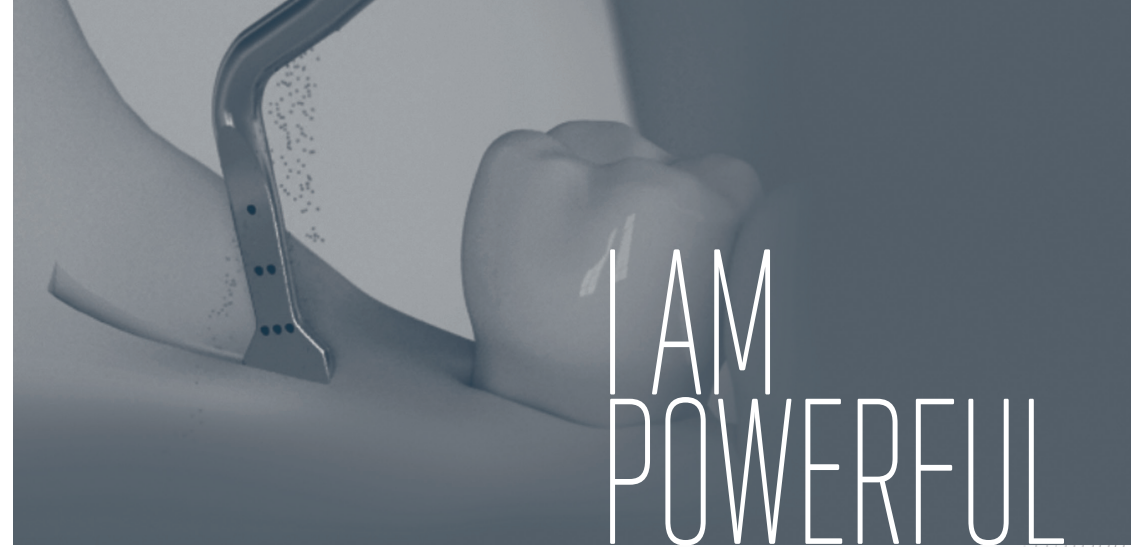

Watch our Youtube channel:



Non contractual document - Ref: D87399 - V6 - 03/2016 - Copyright © 2015 SATELEC® - All rights reserved. No information or part of this document may be reproduced or transmitted in any form without the prior permission of ACTEON®.



Courtesy of Dr Serge Dibart

COMPENDIUM
Ultrasonic Piezo Surgery



BOOKS

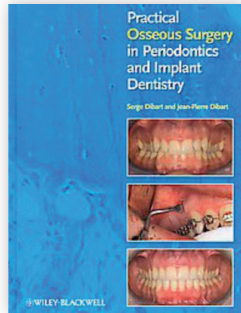
**PRACTICAL OSSEOUS SURGERY IN
PERIODONTICS AND IMPLANT DENTISTRY**
..... p4

**CLINICAL SUCCESS IN BONE SURGERY
WITH ULTRASONIC DEVICES**
..... p5

PRACTICAL OSSEOUS SURGERY IN PERIODONTICS AND IMPLANT DENTISTRY

S. Dibart, J-P. Dibart
Wiley-Blackwell, 2011

The book presents osseous surgery in periodontal, implant and orthodontic treatments.

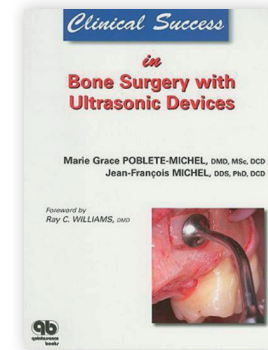


“ Extraction, IntraLift® (sinus lift by the crestal approach) and the Piezocision™ techniques with Piezotome® ultrasonic surgical units are developed. ”

CLINICAL SUCCESS IN BONE SURGERY WITH ULTRASONIC DEVICES

M-G. Poblete-Michel, J-F. Michel
Foreword by Ray C. WILLIAMS, Quintessence International, 2009

“Technical aspects, indications and contraindications for bone surgery in periodontology and implant dentistry, devices and instrumentation, preoperative evaluation and premedication, intraoral and extraoral donor sites”.



“ The piezoelectric surgery accordingly offers comfort, safety, and precision to the surgeon during delicate interventions. ”



ARTICLES

PIEZO ULTRASONIC SURGERY PERFORMANCES	p8
LATERAL SINUS LIFT	p12
CRESTAL SINUS LIFT - INTRALIFT™	p14
RIDGE EXPANSION - CREST SPLITTING	p22
ORTHODONTICS - PIEZOCISION™	p25
EXTRACTION	p30

IN VIVO ASSESSMENT OF BONE HEALING FOLLOWING PIEZOTOME ULTRASONIC INSTRUMENTATION

J. Reside, E. Everett, R. Padilla, R. Arce, P. Miguez, N. Brodala, I. De Kok, S. Nares

Clinical Implant Dentistry and Related Research, June 2013

Keywords

Gene expression, histology, microCT, Piezoelectric surgery, Piezotome®.

Abstract

Purpose:

This pilot study evaluated the molecular, histologic, and radiographic healing of bone to instrumentation with piezoelectric or high speed rotary (R) devices over a 3-week healing period.

Materials and methods:

Fourteen Sprague-Dawley rats (Charles River Laboratories International, Inc., Wilmington, MA, USA) underwent bilateral tibial osteotomies prepared in a randomized split-leg design using Piezotome® (P1) (Satelec® Acteon®, Merignac, France), Piezotome® 2 (P2) (Satelec® Acteon®), High-speed R instrumentation, or sham surgery (S).

At 1 week, an osteogenesis array was used to evaluate differences in gene expression while quantitative analysis assessed percentage bone fill (PBF) and bone mineral density (BMD) in the defect, peripheral, and distant regions at 3 weeks. Qualitative histologic evaluation of healing osteotomies was also performed at 3 weeks.

Results:

At 1 week, expression of 11 and 18 genes involved in bone healing was significantly ($p < .05$) lower following P1 and P2 instrumentation, respectively, relative to S whereas 16 and 4 genes were lower relative to R. No differences in PBF or BMD were detected between groups within the osteotomy defect. However, significant differences in PBF ($p = .020$) and BMD ($p = .008$) were noted along the peripheral region between P2 and R groups, being R the group with the lowest values. Histologically, smooth osteotomy margins were present following instrumentation using P1 or P2 relative to R.

Conclusion:

Piezoelectric instrumentation favors preservation of bone adjacent to osteotomies while variations in gene expression suggest differences in healing rates due to surgical modality. Bone instrumented by piezoelectric surgery appears less detrimental to bone healing than high-speed R device.

“ With both Piezotome® piezoelectric surgical units, osteotomy margins were smooth and much better defined, suggesting minimal postoperative necrosis of the marginal bone during healing process.

Osteotomies performed with Piezotome® 2 went faster than Piezotome® 1. However, the increase of power of generation 2 has no effect on bone tissues or healing process.

No genetic, histologic, or radiographic evidence of necrosis or exuberant inflammation over the 3 week healing period was found. ”

MICROMORPHOMETRICAL ANALYSES OF FIVE DIFFERENT ULTRASONIC OSTEOTOMY DEVICES AT THE RABBIT SKULL

S. Hollstein, E. Hoffmann, J. Vogel, F. Heyroth, N. Prochnow, P. Maurer

Clinical Oral Implants Recherche 23, 2012; 713–718, 2012

Keywords

Confocal laser scanning microscopy, environmental scanning electron microscopy, piezosurgery, ultrasonic osteotomy.

Abstract

Objectives:

The recently introduced ultrasonic osteotome procedure is an alternative to conventional methods of osteotomy. The aim of the present study was to establish the differences between five recently introduced ultrasonic osteotomes and to perform micromorphological and quantitative roughness analyses of osteotomized bone surfaces.

Materials and methods:

Fresh, standard-sized bony samples were taken from a rabbit skull using the following ultrasonic osteotomes: the Piezosurgery® 3 with insert tip OT7, Piezosurgery® Medical with insert tip MT1-10, Piezon Master Surgery® with insert tip SL1, VarioSurg® with inert tip SG1, and Piezotome® 2 with insert tip BS1 II. The required duration of time for each osteotomy was recorded. The prepared surfaces were examined via light microscopy, environmental surface electron microscopy (ESEM), and confocal laser scanning microscopy (CLSM).

Results:

All of the investigated piezoelectric osteotomes preserved the anatomical structure of bone. The mean roughness values of the osteotomized bone edge obtained using the investigated piezoelectric osteotomes were as follows: 2.47 μm (Piezosurgery® 3), 9.79 μm (Piezosurgery® Medical), 4.66 μm (Piezon Master Surgery®), 6.38 μm (VarioSurg®), and 6.06 μm (Piezotome® 2). Significantly higher roughness values were observed when using the Piezosurgery® Medical in comparison with those achieved by the Piezosurgery® 3 ($P < 0.0001$) and Piezon Master Surgery® ($P = 0.002$). Different osteotomy durations were achieved using the different piezoelectric osteotomes: 144 s (Piezosurgery® 3), 126 s (Piezosurgery® Medical), 142 s (Piezon Master Surgery®), 149 s (VarioSurg®), and 137 s (Piezotome® 2).

Conclusion:

In the present study, micromorphological differences following the use of various ultrasonic devices were clearly identified. According to this study, it can be concluded that the power and the composition of the teeth of the insert tip might impact procedure duration and cutting qualities.

“ This article compares the osteotomy performed with 5 surgical piezoelectric devices. In that goal, the authors have performed micro-morphological and quantitative roughness analyses of osteotomized bone surfaces. All units presented bone micro-structure preservation. However, the power and the composition of the teeth of the insert tip might impact procedure duration and cutting qualities. A very quick performance was observed using Piezotome® 2 unit. The selective cut prevents all injuries to adjacent meninges. ”

INCREASED INTRAOSSEOUS TEMPERATURE CAUSED BY ULTRASONIC DEVICES DURING BONE SURGERY AND THE INFLUENCES OF WORKING PRESSURE AND COOLING IRRIGATION

F. Birkenfeld, M.E. Becker, S. Harder, R. Lucius, M. Kern
The International Journal of Oral & Maxillofacial Implants; 27:1382-1388, 2012

Keywords

Cutting performance, intraosseous temperature development, ultrasonic bone surgery.

Purpose:

The purpose of this study was to investigate the increases in intraosseous temperature generated by a modern ultrasonic device for bone surgery (UDBS) and the influences of working pressure and cooling irrigation on this temperature.

Materials and methods:

Twenty human mandibular bone specimens (20 x 15 x 5 to 7 mm) were used; three vertical cuts were performed for a duration of 12 seconds per cut. Each bone specimen was machined with a different combination of working pressure (1.5, 2.0, 3.0, 4.0, or 6.0 N) and cooling irrigation (0, 30, 60, or 90 mL/min), and intraosseous temperatures were measured.

Harmful temperature development was defined as an increase of more than 10°C for the 75th percentile and/or a maximum increase of more than 15°C. Cutting performance was also measured.

Results:

Harmless intraosseous temperature development was identified for working pressures of 1.5 N and 2.0 N with cooling irrigations of 30, 60, and 90 mL/min and for 3.0 N at 90 mL/min. The maximum temperature observed was 72°C (6.0 N with 60 mL/min). The mean cutting performance values were 0.21 ± 0.02 mm/s for 6.0 N, 0.21 ± 0.06 mm/s for 3.0 N, 0.20 ± 0.01 mm/s for 4.0 N, 0.11 ± 0.05 mm/s for 1.5 N, and 0.08 ± 0.03 mm/s for 2.0 N.

Conclusion:

To prevent tissue damage in dental bone surgery, a minimum coolant amount of 30 mL/min is recommended. The working pressure should be chosen with great care because of its significant influence on intraosseous temperature. Doubling of the working pressure from 1.5 to 3.0 N requires a tripling of the coolant (30 to 90 mL/min) to prevent tissue damage. A working pressure above 3.0 N did not result in improved cutting performance.

“ To prevent damage in dental bone surgery when using an ultrasonic device, a minimum coolant amount of 30ml/min is recommended. A working pressure above 3N may not enhance the cutting performance. ”

PERFORMANCE OF ULTRASONIC DEVICES FOR BONE SURGERY AND ASSOCIATED INTRAOSSEOUS TEMPERATURE DEVELOPMENT

S. Harder, S. Wolfart, C. Mehl, M. Kern
The International Journal of Oral & Maxillofacial Implants Volume 24, Number 3, 2009

Keywords

Cutting performance, intraosseous temperature development, material testing, ultrasonic bone surgery.

Purpose:

The purpose of this study was to evaluate and to compare the bone-cutting performance and intraosseous temperature development of three modern ultrasonic devices for bone surgery (UDBS).

Materials and methods:

The following UDBS and associated cutting tips (straights bone saws) were used in this study: (1) Piezosurgery® II professional, tip OT 7 (Mectron®); (2) Piezotome®, tip BS1 (Acteon®) and (3) SurgySonic®, tip ES007 (American dental system/Günther Jerney). In the experimental setup UDBS, handpieces were immobilized, and bone specimens from the middiaphysis of a bovine femur were moved in a longitudinal direction under the cutting tip to a standardized depth of 3.0 mm. Statistical analysis was performed using the Wilcoxon rank sum test.

Results:

The median increase (25th through 75th percentiles) of the local intraosseous temperature was 3.0°C (2.2°C to 4.2°C) for the SurgySonic®, 2.2°C (1.8°C to 3.2°C) for the Piezosurgery® II, 1.1°C (0.7°C to 1.6°C) for the Piezotome®. The median cutting performance was 0.31 mm/s (0.11 to 0.46 mm/s) for the Piezotome®, 0.25 mm/s (0.23 to 0.27 mm/s) for the for the Piezosurgery® II and 0.04 mm/s (0.03 to 0.05mm/s) for the SurgySonic®.

Conclusion:

Among the three tested UDBS, the Piezotome® and the Piezosurgery® II showed a significantly higher cutting performance than the SurgySonic®. The Piezotome® produced the smallest increase in intraosseous temperature.

“ Acteon® & Mectron® showed a significantly higher cutting performance, whereas Acteon® produced the least increase of intraosseous temperature. Differences in the cutting performance and intraosseous temperature development of the tested devices seemed to be influenced by the design of the cutting tips of the bone saws used in this investigation. On Acteon® device, was observed a deeper penetration into the bone. Its cutting tip showed more homogenous and sharper spike geometry and more roughened spike surfaces than other cutting tips. ”

THE EFFECT OF PIEZOELECTRIC USE ON OPEN SINUS LIFT PERFORATION: A RETROSPECTIVE EVALUATION OF 56 CONSECUTIVELY TREATED CASES FROM PRIVATE PRACTICES

N.J. Toscano, D. Holtzclaw, P.S. Rosen
Journal of Periodontology, January 2010

Keywords

Alveolar ridge augmentation; bone transplantation; complications; dental implants; maxillary sinus; ultrasonic therapy.

Background:

The lateral window approach to maxillary sinus augmentation is a well-accepted treatment option in implant dentistry. The most frequent complication reported with traditional techniques has been the perforation of the Schneiderian membrane, with perforation rates ranging from 11% to 56%. The purpose of this retrospective, consecutive case series from two private practices was to report on the rate of Schneiderian membrane perforations and arterial lacerations when a piezoelectric surgical unit was used in conjunction with hand instrumentation to perform lateral window sinus elevations.

Methods:

Clinical data (Schneiderian membrane perforation, Underwood septa, and laceration of the lateral arterial blood supply to the maxillary sinus) were obtained retrospectively from two private practices and pooled for analysis. The information was collated after an exhaustive chart review. Fifty-six consecutively treated lateral window sinus lifts were performed on 50 partially or completely edentate patients.

Results:

Zero perforations of the Schneiderian membrane occurred during the piezoelectric preparation of the lateral antrastomies, whereas two perforations were noted during subsequent membrane elevations using hand instrumentation. In both instances, membrane perforations were associated with sinus septa. The overall sinus perforation rate was 3.6%. Arterial branches of the posterior superior alveolar artery were encountered in 35 cases, and there were zero instances of arterial laceration.

Conclusion:

This retrospective case series from clinical private practices confirmed that a lateral window approach to sinus elevation incorporating piezoelectric technology in conjunction with hand instrumentation was an effective means to achieve sinus elevation while minimizing the potential for intraoperative complications. Further prospective and randomized controlled studies are warranted to qualify these observations.

“*Piezotome[®], SATELEC[®] ACTEON[®] unit was used to performed the 56 sinus lifts. 20 to 30% prevalence of Schneiderian membrane perforations was reported with the used of high-speed rotating instruments in the preparation of lateral sinus windows. The bony thickness of lateral maxillary sinus walls averages 0.91mm, and the adjacent Schneiderian membrane averages 0.15mm in thickness, the traditional use of high-speed rotating instruments for the preparation of lateral sinus antrastomies requires exacting attention to detail. Because piezoelectric surgery does not cut soft tissues, it stands to reason that proper piezoelectric use in the preparation of lateral sinus antrastomies would reduce the risk of Scheiderian membrane perforation.*”

FOCUS ON THE CLINIC: POSTERIOR MAXILLARY IMPLANT PLACEMENT AFTER PIEZOSURGICAL SINUS AUGMENTATION

J-F. Michel, M-G. Poblete Michel
Forum implantologicum, Volume 8, Issue 1, 2012

“The clinical case presented is of a 44 year-old Caucasian female patient. She consulted to replace a maxillary removable partial denture that she could no longer tolerate”.

“*- Perform prompt minimally invasive interventions;
- To reduce the number of implants needed in oral reconstruction;
- To adapt the oral reconstruction to the requirements of the future prosthetic replacements.*”

SCHNEIDERIAN MEMBRANE DETACHMENT USING TRANSCRESTAL HYDRODYNAMIC ULTRASONIC CAVITATIONAL SINUS LIFT: A HUMAN CADAVER HEAD STUDY AND HISTOLOGIC ANALYSIS

A. Troedhan, A. Kurrek, M. Wainwright, S. Jank
Journal of Oral and Maxillofacial Surgery, 72 (8):1503.e1-10, 2014

Abstract

Purpose:

Recent studies have suggested the osteogenic layer of the periosteum at the base of the sinus membrane to play a key role in bone regeneration after sinus lift procedures. Thus, atraumatic detachment of the sinus membrane with an intact periosteum seems mandatory. The present histologic study of fresh human cadaver heads investigated the detachment behavior and histologic integrity of the detached periosteum after application of the transcresal hydrodynamic ultrasonic cavitational sinus lift (tHUCSL-INTRALIFT).

Materials and Methods:

A total of 15 sinuses in 8 fresh human cadaver heads were treated using tHUCSL-INTRALIFT. After surgery, they were checked macroscopically for damage to the sinus membrane and then processed for histologic inspection under light microscopy. A total of 150 histologic specimens, randomly selected from the core surgical sites, were investigated using hematoxylin-eosin (HE), Azan, and trichrome staining.

Results:

None of the 150 inspected specimens showed any perforation or dissection of the periosteum from the subepithelial connective tissue and respiratory epithelium and were fully detached from the bony antrum floor. The connecting Sharpey fibers revealed to be cleanly separated from the sinus floor in all specimens.

Conclusion:

The results of the present study suggest tHUCSL-INTRALIFT should be used to perform predictable and safe detachment of the periosteum from the bony sinus floor as a prerequisite for undisturbed and successful physiologic subantral bone regeneration.

“ All 150 specimens investigated by light microscopy revealed a cleanly separated periosteum from the bony sinus floor, providing an intact osteogenic layer of the periosteum to rest on scaffold-creating biomaterials. Hydraulic detachment exerts only uniform, small pressure forces that will be evenly distributed between the periosteum and the bony sinus floor, fully avoiding producing tensile shearing forces, and thus might avoid transgression of the mechanical limits of the sinus membrane's periosteum. tHUCSL is a reliable and safe sinus lift procedure that can prevent iatrogenic restriction of the sinus membranes' innate osteogenic potential. ”

PRIMARY IMPLANT STABILITY IN AUGMENTED SINUSLIFT-SITES AFTER COMPLETED BONE REGENERATION: A RANDOMIZED CONTROLLED CLINICAL STUDY COMPARING FOUR SUBANTRALLY INSERTED BIOMATERIALS

A. Troedhan, I. Schlichting, A. Kurrek, M. Wainwright
Scientific reports, 4 : 5877, 2014

Abstract

Implant-Insertion-Torque-Value (ITV) proved to be a significant clinical parameter to predict long term implant success-rates and to decide upon immediate loading. The study evaluated ITVs, when four different and commonly used biomaterials were used in sinuslift-procedures compared to natural subantral bone in two-stage-implant-procedures. The tHUCSL-INTRALIFT-method was chosen for sinuslifting in 155 sinuslift-sites for its minimal invasive transcresal approach and scalable augmentation volume. Four different biomaterials were inserted randomly (easy-graft CRYSTAL n = 38, easy-graft CLASSIC n = 41, NanoBone n = 42, BioOss n = 34), 2 ccm in each case. After a mean healing period of 8,92 months uniform tapered screw Q2-implants were inserted and Drill-Torque-Values (DTV) and ITV were recorded and compared to a group of 36 subantral sites without need of sinuslifting. DTV/ITV were processed for statistics by ANOVA-tests. Mean DTV/ITV obtained in Ncm were: Control Group 10,2/22,2, Bio-Oss 12,7/ 26,2, NanoBone 17,5/33,3, easy-graft CLASSIC 20,3/45,9, easy-graft CRYSTAL 23,8/56,6 Ncm, significance-level of differences throughout p < 0,05. Within the limits of this study the results suggest self-hardening solid-block-like bone-graft-materials to achieve significantly better DTV/ITV than loose granulate biomaterials for its suspected improvement of vascularization and mineralization of the subantral scaffold by full immobilization of the augmentation site towards pressure changes in the human sinus at normal breathing.

“ The tHUCSL-INTRALIFT was chosen to provide the least invasive sinuslift-procedure with a possible augmentation volume comparable to lateral approach sinus-lift techniques and the least risk of sinus-membrane perforation. Using tHUCSL-INTRALIFT, unbiased results and almost negligible iatrogenic failure-interference with natural subantral bone regeneration can be achieved by reproducible clean and undissected separation of the osteogenic layer of the sinus-membrane from the antrum-floor. The tHUCSL-INTRALIFT by its well documented innate atraumaticity seems not only to provide steady clinical results in praxem but might be suitable as standard-procedure in clinical research to obtain unbiased results when subantral grafting materials are investigated for their bone regeneration behaviour and final physical bone-density quality. ”

COMPARISON OF 2 CRESTAL SINUS FLOOR LIFT TECHNIQUES PERFORMED ON HUMAN CADAVERS

J. Llopet, M. Montaudon, E. Guillaud, B. Ella
Implant Dentistry – Volume 23, Number 5, 2014

Keywords

Osteotomy, Sinus Lift, Intralift™, Summers, Piezosurgery.

Objectives:

To compare the effectiveness of 2 different techniques to lift the maxillary sinus floor through a crestal approach on fresh human cadaver heads: the Intralift technique using Piezosurgery and the Summers technique using osteotomy.

Materials and methods:

Two different protocols were simulated on 11 fresh human cadaver heads or 22 maxillary sinuses. Inclusion criteria were: bilateral edentulous maxilla with a residual ridge height between 3 and 9 mm. CT scans were performed before and after surgery on all fresh cadaver heads. Both Intralift and Summers techniques were performed on the same maxilla on the 2 sinuses. The surgical procedure was performed by 2 independent operators, 1 experienced and 1 novice to compare the 2 results. The parameters assessed were the procedure duration and the sinus membrane preservation.

Results:

The procedure duration was shorter when the operator was more experienced ($P = 0.03$). There was a correlation between the operator dexterity and the time required for surgery. The Intralift technique seemed safer for sinus membrane preservation.

Conclusion:

The Intralift technique is an interesting alternative to the Summers technique.

“ The Intralift technique seems less invasive for preserving the sinus membrane regardless of the operator. The results tend to confirm a better surgical comfort with the Intralift technique than with the Summers. The novice operator seemed immediately more comfortable with the Intralift technique. Moreover, it has the advantage to be less traumatic, whereas the Summers technique is described as an aggravating factor for benign positional paroxysmal vertigo. ”

THE TRANSCRESTAL HYDRODYNAMIC ULTRASONIC CAVITATIONAL SINUSLIFT: RESULTS OF A 2-YEAR PROSPECTIVE MULTICENTRE STUDY ON 404 PATIENTS, 446 SINUSLIFT SITES AND 637 INSERTED IMPLANTS

A. Troedhan, A. Kurrek, M. Wainwright, I. Schlichting, B. Fischak-Treitl,
M. Ladentrog
Open Journal of Stomatology, 3, 2013

Keywords

Transcrestal, Hydrodynamic sinuslift, Bone Augmentation, Implants, Ultrasound Surgery, Maxillary Sinus.

Introduction:

In 2006 an ultrasound-surgery-based method to hydrodynamically detach the sinus-membrane utilizing the ultrasonic cavitation effect - the tHUCSL - was developed and a surgical protocol established. The aim of the study was to determine the indication-range and success-rate of this novelty procedure.

Materials and methods:

Between 2007 and 2009, 404 patients were treated by 6 oral surgeons of different experience-levels with the tHUCSL in 446 sinus-sites. 637 implants were inserted and then prosthodontically treated and observed and documented until December 2011. The subantral space was augmented via the 3 mm transcrestal approach with an augmentation volume of 1.9 ccm (+/- 0.988 ccm) and an augmentation height of 10.7 mm (+/- 2.85 mm).

Results:

Within the survey-period 15 (2.35%) of the 637 inserted implants were lost, mostly before implant loading due to postsurgical infection and non-osseointegration in the augmentation site. 1 implant was lost after implant loading and prosthetic treatment within 1 year after loading. The overall success rate with functional implants in site is 97.65% evenly distributed among the participating surgeons. 86% of the patients were observed with no postsurgical swelling and 87% no postsurgical pain.

Discussion:

The results suggest the tHUCSL to be a safe minimal-invasive alternative to traditional lateral approach and transcrestal osteotome sinuslift-procedures applicable to all anatomical situations.

“ The tHUCSL-INTRALIFT-procedure can be trained with a small investment of time by the dentist and be applied by every dentist with a basic training in implantology with almost the same success-rate as long-term experienced oral surgeons as the study results suggest. The standardized hydrodynamic pressure described in the surgical protocol combined with the ultrasound cavitation effect distributes the detaching forces equally between the sinus membrane and the bony antrum of the sinus. The tHUCSL-INTRALIFT is compatible to all implant systems with an implant diameter of more than 3 mm and most of all applicable to all anatomical conditions of the alveolar crest and the maxillary sinus which can be considered a major advantage. ”

BIOLOGICAL PRINCIPLES AND PHYSIOLOGY OF BONE REGENERATION UNDER THE SCHNEIDERIAN MEMBRANE AFTER SINUS LIFT SURGERY: A RADIOLOGICAL STUDY IN 14 PATIENTS TREATED WITH THE TRANSCRESTAL HYDRODYNAMIC ULTRASONIC CAVITATIONAL SINUS LIFT (INTRALIFT®)

A. Troedhan, A. Kurrek, M. Wainwright

International Journal of Dentistry, Volume 2012, Article ID 576238, 12 pages, 2012

Introduction:

Sinus lift procedures are a commonly accepted method of bone augmentation in the lateral maxilla with clinically good results. Nevertheless the role of the Schneiderian membrane in the bone-reformation process is discussed controversially. Aim of this study was to prove the key role of the sinus membrane in bone reformation in vivo.

Materials and methods:

14 patients were treated with the minimal invasive tHUCSL-Intralift®, and 2 ccm collagenous sponges were inserted subantrally and the calcification process followed up with CBCT scans 4 and 7 months after surgery.

Results:

An even and circular centripetal calcification under the sinus membrane and the antral floor was detected 4 months after surgery covering 30% of the entire augmentation width/height/depth at each wall. The calcification process was completed in the entire augmentation volume after 7 months. A loss of approximately 13% of absolute augmentation height was detected between the 4th and 7th month.

Discussion:

The results of this paper prove the key role of the sinus membrane as the main carrier of bone reformation after sinus lift procedures as multiple experimental studies suggested. Thus the importance of minimal invasive and rupture free sinus lift procedures is underlined and does not depend on the type of grafting material used.

“ All 14 tHUCSL Intralift® Sinus lift procedures were conducted without perforation of the sinus membrane, and no postsurgical complications suspicious of sinus-membrane perforations occurred. It proves the key role of the sinus membrane as the main carrier of bone reformation after Sinus Lift procedures as multiple experimental studies suggested the importance of minimal invasive and rupture free sinus lift procedures is underlined and does not depend on the type of grafting material used. ”

RUPTURE LENGTH OF THE SINUS MEMBRANE AFTER 1.2MM PUNCTURE AND SURGICAL SINUS ELEVATION: AN EXPERIMENTAL ANIMAL CADAVER STUDY

S. Jank, A. Kurrek, M. Wainwright, V.E. Bek, A. Troedhan

Oral Surgery Oral Medicine Oral Pathology Oral Radiology and Endodontology ; 112(5):568-72 ; Nov 2011

Objectives:

To evaluate the rupture length of the sinus membrane after applying a defined 1.2 mm defect comparing 3 different techniques: Summers lift, balloon-assisted technique (BASL), and hydrodynamic ultrasonic cavitational sinus lift (HUCSL).

Study design:

Thirty fresh sheep heads (60 maxillary sinuses) were investigated. The sinus membrane was ruptured using a 1.2 mm pilot drill. Then Summers lift, BASL, and HUCSL were each performed on 20 sinuses, creating a 5 mm vertical lift of the sinus membrane. The length of the ruptured sinus membrane was measured before and after the experiment. The results of the different sinus lift techniques were compared using *t* tests.

Results:

The *t* test showed that the Summers lift leads to a significantly higher rupture length ($P = .05$) than BASL. The comparison between Summers lift and HUCSL showed a significantly higher rupture length with the Summers lift ($P < .005$). The same significance ($P < .005$) was found when BASL was compared with HUCSL. Comparing the increasing rupture length of the sinus membrane during the experiment, the *t* test showed a significantly greater rupture using BASL or the Summers lift compared with HUCSL.

Conclusion:

The HUCSL technique yielded the lowest increase of rupture length compared with BASL and Summers lift. The technique therefore shows the lowest risk of a growing rupture of the sinus membrane in case of an iatrogenic puncture during preparation of the transcrestal approach.

“ The HUCSL (Intralift® - ACTEON® Piezotome® equipment), was designed to elevate the sinus membrane without any tearing forces using an ultrasonic oscillating water stream to lift up the sinus membrane from the bone. The Intralift® technique showed the best results of the 3 investigated methods (Summers lift, BASL, HUCSL), and that it yielded the lower risk of an enlarged rupture of the sinus membrane in case of an iatrogenic puncture during preparation of the transcrestal approach. Compared with the literature, which reports a need of covering only defects which are >2 mm, it can be concluded that Intralift® could decrease postoperative complications after augmentation, because the percentage of ruptures is low and their size does not extend the critical size of 2 mm. ”

HYDRODYNAMIC ULTRASONIC SINUS FLOOR ELEVATION - AN EXPERIMENTAL STUDY IN SHEEP

A. Troedhan, A. Kurrek, M. Wainwright, S. Jank
Journal of Oral Maxillofacial Surgery, 68:1125-1130, 2010

Purpose:

The aim of the present study was to evaluate the pressure forces appearing to elevate the sinus membrane by comparing the hydraulic and pneumatic pressure. Also, the relation between the time and volume of the applied liquid and the achieved lift-volume were determined.

Materials and methods:

A total of 190 fresh, half sheep heads were used for the present investigation. An ultrasound surgical device (Piezotome®; Acteon®, Bordeaux, France) was tested to evaluate the pressure increase at different flow rates. The elevation volume at different flow rates and activation times of the ultrasound hand piece were measured.

Results:

To detach the sinus membrane pneumatically from the sinus floor, a mean average pressure of 29.54 millibars was required. Using the hydraulic technique, a mean average pressure of 19.8 millibars was determined. Comparing the different flow rates, the elevated volume increased to 0.52 ml when a flow of 60 ml/minute was used. Using an activation time of 20 seconds, a lifted volume of 3.92 ml could be measured on average. If the flow was set to a maximum of 60 ml/minute, the created volume increased to 5.58 ml. A comparison using the x2 test showed a significant correlation ($P = .03$) between the application time and the created sinus lift volume. Even at high flow rates of 60 ml/minute of the activated Piezotome® for a 20 second period, no rupture of the sinus membrane of the sheep head occurred in 190 experiments.

Conclusion:

From these results, we have concluded that hydrodynamic ultrasound could be used as an alternative method for sinus floor elevations of any size and volume with a mere 3-mm-diameter transcrestal approach, if findings from clinical investigations confirm the results of the present animal study.

“ To detach the sinus membrane pneumatically (Balloon) around 29.54 millibars was required against 19.8 millibars for the hydraulic technique (IntraLift®) with an average lifted volume of 3.92ml. With Piezotome®, no rupture of the sinus membrane of sheep heads occurred. ”

THE INTRALIFT™: A NEW MINIMAL INVASIVE ULTRASONIC TECHNIQUE FOR SINUS GRAFTING PROCEDURES

M. Wainwright, A. Troedhan, A. Kurrek
Implants magazine, Dental Tribune International, Vol.8, Issue 3, 2007

Abstract

The IntraLift® is an alternative to conventional sinus grafting techniques with dramatically reduced trauma and a high patient acceptance. The aim to minimize operation techniques was the drive for the authors to invent this protocol based on the piezoelectric and the microcavitation effect. Regarding the protocol, a traumatization of the Schneiderian membrane is extremely reduced, and even if there is a perforation, the protocol describes the plugging of a collagenous sponge to close the perforation and to continue with the operation protocol. Small areas like single tooth implants or huge edentulous areas can be grafted with an osteotomy from the crestal aspect and, if no lateral augmentation is necessary, only with the atraumatic punch technique. Patients today desire more and more a minimalization of operation techniques combined with a high predictability. This technique is an opportunity to increase the number of patients with compromised maxillary bone situation. New trabecular bone formation was partially visible only after 6 weeks, and in 98%, the treated patients didn't use any analgetics. Hence, an enlarged database and additional studies are necessary to underline the effectiveness of this technique.

“ The IntraLift® is an alternative to conventional sinus grafting techniques with dramatically reduced trauma and high patient acceptance. New trabecular bone formation was partially visible only after 6 weeks, and in 98%, the treated patients didn't use any analgetics. ”

FLAPLESS PIEZOTOME-ENHANCED VERTICAL ALVEOLAR CREST-SPLIT AND HORIZONTAL DISTRACTION OF ALVEOLAR CRESTS (FPECSWT) OF LESS THAN 2 mm WIDTH: RESULTS OF A PROSPECTIVE COMPARATIVE 3-YEAR CLINICAL MULTICENTER-STUDY WITH 239 PATIENTS, 261 CREST-SPLIT SITES AND 488 INSERTED DENTAL IMPLANTS

A. Troedhan, A. Kurrek, M. Wainwright, I. Schlichting
Open Journal of Stomatology, 2015

Keywords

Dental Implantology, Bone-Management, Guided Bone Regeneration, Piezosurgery, Ultrasonic Surgery, Crest-Split, Ridge-Split, Distraction Osteogenesis, Biomaterials, Dental Implants

Abstract

Alveolar crest-splitting and horizontal distraction is an established surgical technique to enable implant insertion into the narrow, lateral atrophic alveolar crest. This surgical technique is challenging for the oral surgeon and restricted to crest-widths of 3 - 5 mm: significant procedural bone loss at osteotomy, the need to prepare a full thickness mucoperiosteal flap and milling a baseline-osteotomy to weaken the bone for distraction inhere significant risks of accidental fractures. Aim of the study was to investigate if the recently developed novel Flapless Piezotome enhanced Crest-Splitting and Widening Technique (FPeCSWT) could safely narrow down the indication for this procedure to narrow alveolar crests of widths of even less than 2 mm in a three-year survey period. 239 patients underwent 261 FPeCSWT-surgeries and 488 implants were inserted simultaneously in the upper and the lower jaw and clinical parameters such as intrasurgical complications, patient morbidity, implant loss and vertical bone loss (VBL) in the first three years after surgeries were recorded comparing sites with less than 2 mm width with sites of more than 2 mm. After three years a significant difference ($p = 0.24$) of VBL could be observed between the group with less than 2 mm crest-width (mean: 0.97 mm, max: 2.0 mm/min: 0.0 mm; SD: 0.41) compared with the group with more than 2 mm crest-width (mean: 0.69 mm, max: 1.5 mm/min: 0.0 mm; SD: 0.36) but was still significant lower when compared with the results of similar studies published with a mucoperiosteal-flap approach and baseline bone-cut. The cumulative 3-year-implant-survival-rate was 98.8%, no accidental fracture of the distracted buccal bone-plate occurred. The results of the study suggest that the FPeCSWT narrows safely down the indication for crest-splitting to also crest-widths of only 1 mm. The procedure is highly predictable and significantly reduces the challenge of surgical skills and leads to negligible patient-morbidity. The higher VBL in crest-widths of less than 2 mm can easily be compensated by subcrestal placement of implants.

“ FPeCSWT still achieves significant better results than traditional or other ultrasonic-surgical methods of crest-splitting reporting buccal vertical bone loss of 3 - 4 mm in narrow alveolar crests of 2 mm. With no single accidental iatrogenic vertical fracture or fracture of the distraction-baseline the FPeCSWT seems to provide more constant clinical results with calculable minimal vertical resorptions. ”

VERTICAL ALVEOLAR CREST SPLIT AND WIDENING – AN EXPERIMENTAL STUDY ON COW RIBS, ULTRASONIC TOOL DEVELOPMENT AND TEST ON HUMAN CADAVER HEADS

A. Troedhan, A. Kurrek, M. Wainwright
Surgical Techniques Development, 2:e10 ; 2012

Abstract

Vertical alveolar crest splitting and horizontal distraction of narrow alveolar crests is limited when rotating and low frequency oscillating tools are used due to large amounts of procedural bone loss and poor handling provisions. Aim of this study was to determine the safest osteotomy depth and to develop ultrasonic-surgery-tips to enable flapless vertical crest splitting and distraction of narrow alveolar crests of 2 mm or less. The safest osteotomy depth was determined on a cow-rib-model. To enable a flapless crest splitting and widening procedure, prototype-tips for the Piezotome®-device were developed and tested against mechanical tools (widening screws and distractors) on cow-ribs, as well as their safe use in the hands of novice-surgeons on human cadaver heads. A minimum vertical osteotomy depth of 7-8 mm revealed the least fracture rates (3%). The use of the ultrasonic distraction tools showed the least risk of procedural failures (2%). Twenty-three Piezotome®-trainees performed the procedure with the developed tips on fresh full human cadaver skulls with a success rate of 100%. The results of this study suggest that, with the use of ultrasonic surgical devices, the indication for vertical crest-splitting can be narrowed down to a crest width of 2 mm and even less and that it can be performed flapless, thus leaving the physiological bone-periosteum system fully intact.

“ The results of this study suggest that, with the use of ultrasonic surgical device Piezotome® 2, the indication for vertical crest-splitting can be narrowed down to a crest width of 2 mm and even less and that it can be performed flapless, thus leaving the physiological bone-periosteum system fully intact. ”

RECONSTRUCTION OF POSTERIOR MANDIBULAR ALVEOLAR RIDGE DEFICIENCIES WITH THE PIEZOELECTRIC HINGE-ASSISTED RIDGE SPLIT TECHNIQUE: A RETROSPECTIVE OBSERVATIONAL REPORT

D.J. Holtzclaw, N.J. Toscano, P. S. Rosen

Journal of Periodontology, Vol. 81, No. 11, Pages 1580-1586, DOI 10.1902/jop.2010.100093, 2010

Keywords

Alveolar ridge augmentation, bone regeneration, grafting, bone, mandible, partially edentulous jaw.

Methods:

Thirteen patients with 17 horizontal alveolar ridge deficiencies of the posterior mandible were treated with the piezoelectric hinge-assisted ridge split procedure. After an average healing period of 14 weeks, dental implants were placed into the augmented sites. Intrasurgical alveolar ridge measurements taken at the initial surgery and subsequently at the time of implant placement documented the horizontal gains achieved by this procedure.

Results:

Overall mean gain in horizontal width was 4.03 mm (\pm 0.67). For single implant-site augmentations, the mean gain was 3.38 mm (\pm 0.25). For multiple adjacent implant-site augmentations, mean gain was 4.25 mm (\pm 0.62). A total of 31 dental implants were successfully placed in all sites and none required additional augmentation procedures. There were no instances of adverse outcomes, such as neurosensory deficits or sequestration of mobilized buccal plates. After a minimum of 6 months of loading, all dental implants have been successful.

Conclusion:

This retrospective observational report demonstrates that the piezoelectric hinge-assisted ridge split procedure can achieve substantial gains in horizontal ridge width of the edentulous posterior mandible without associated morbidity. Further prospective and larger observational studies are warranted to see if this is true over a larger patient population and to compare this technique to other more traditionally used approaches.

“ All patients healed uneventfully with no instances of infection, sequestration of the mobilized buccal plate, or neurosensory deficits. Overall mean gains in horizontal width were 4.03 mm (\pm 0.67). Anecdotal observations made of the ridge split surgical sites included regenerated bone being well vascularized and that bone density was consistently Type II and occasionally Type I bone. ”

TISSUE RESPONSE DURING PIEZOCISION-ASSISTED TOOTH MOVEMENT: A HISTOLOGICAL STUDY IN RATS

S. Dibart, C. Yee, J. Surmenian, J-D. Sebaoun, S. Baloul, E. Goguet-Surmenian, A. Kantarci

European Journal of Orthodontics, 36(4):457-64, 2014

Objectives:

Piezocision is a novel, minimally invasive technique combining micro-incisions and decortications made by a piezotome in order to enhance the rate of orthodontic tooth movement. The combined technique allows simultaneous hard and/or soft tissue grafting via selective tunnelling to correct gingival recessions or bone deficiencies. The present study was designed to evaluate the effects of Piezocision on bone with or without tooth movement on a rat model.

Materials and Methods:

Ninety-four Sprague-Dawley rats were divided into four groups: no treatment (n = 3), TM (tooth movement alone; n = 21), PS (Piezocision alone; n = 35), and PS + TM (Piezocision and tooth movement; n = 35). In each group, seven time points were studied: 1, 3, 7, 14, 28, 42, and 56 days. After sacrifice, the maxillae were removed, defleshed, stained with haematoxylin and eosin for morphometric analyses and tartrate-resistant acid phosphatase for osteoclastic activity.

Results:

Three days after the surgery, the bone content decreased significantly in the PS and PS + TM groups compared to baseline ($P < 0.01$) and the TM group ($P < 0.05$). This trend continued until Day 28 and was particularly evident in the PS + TM group. At Day 56, alveolar bone returned to its baseline levels in all groups. Osteoclastic activity followed similar change pattern found in the amount of bone, suggesting a strong role for the coupling of the resorptive and formative turnover of the bone. Osteoclastic activity increased as soon as Day 1 in the PS (29.0 ± 3.0 , $P < 0.05$) and PS + TM groups (39.0 ± 6.0 , $P < 0.01$) compared to baseline (22.0 ± 4.0). The highest level of osteoclastic activity in TM group was observed at 3 days (64.3 ± 8.0 , $P < 0.01$) with a steady decrease thereafter. The Piezocision-induced osteoclastic activity showed a steady increase up to 7 days in both PS (39.0 ± 7.0 , $P < 0.01$) and PS + TM (51.8 ± 7.0 , $P < 0.01$) groups and decreased thereafter until Day 56.

Conclusion:

Within the limitations of our study (number of animals, duration in time, and limited data on the anabolic activity), our preliminary results suggest that Piezocision-facilitated orthodontic tooth movement increases the rate of movement of the teeth undergoing orthodontic treatment through the coupled remodelling of the alveolar bone. This process is initiated by the osteoclastic activity following surgery and extended via the synergistic relationship between Piezocision and tooth movement.

“ Piezocision led to a sharp and early increase in osteoclastic activity. At day 14, the alveolar bone loss extends approximately to a tooth and a half from the Piezocision site horizontally. It allows to 'skip' a tooth during Piezocision surgery when root proximity is a concern. The healing at the clinical level is much more predictable and much less painful. The amount of demineralization created, through Piezocision, does not make an additional lingual or palatal approach necessary, hence minimizing trauma, discomfort, and enhancing patient's acceptance. ”

SEQUENTIAL PIEZOCISION: A NOVEL APPROACH TO ACCELERATED ORTHODONTIC TREATMENT

E.I. Keser, S. Dibart

American Journal of Orthodontics and Dentofacial Orthopedics, Volume 144, Issue 6, 2013

Abstract

Piezocision-assisted orthodontic treatment is an innovative, minimally invasive surgical technique designed to help achieve rapid orthodontic tooth movement. Microsurgical interproximal openings are made in the buccal gingivae to let the piezoelectric knife create the bone injury that will lead to transient demineralization and subsequent accelerated tooth movement. When this procedure was first described, cuts were made simultaneously at the maxilla and the mandible. In recent years, the technique has evolved to a more staged approach, with selected areas or segments of the arch demineralized at different times during orthodontic treatment to help achieve specific results. The purpose of this article was to report the use of sequential piezocision in the correction of a Class III malocclusion, in a total treatment time of 8 months.

“ Because of the rapid temporary demineralization that occurs after Piezocision as a result of the regional acceleratory phenomenon effect, the orthodontic appointments were scheduled every 2 weeks instead of every 4 weeks. The regional acceleratory phenomenon effect can start as early as 24 hours, usually peaks in 1 to 2 months, and then slows down and disappears as remineralization sets in. Since Piezocision creates a more pliable bone, the effects of a nickel-titanium wire become exaggerated. Sequential piezocision is introduced as a tool to correct a Class III malocclusion in a total treatment time of 8 months. ”

PIEZOCISION™-ASSISTED INVISALIGN® TREATMENT

E.I. Keser, S. Dibart

Compendium, Vol. 32, N°2, 2011

Abstract

In today's fast-paced, esthetic-conscious society, the orthodontic treatment of the adult patient can sometimes be a challenge. Considerable time spent in treatment as well as the use of brackets often deter patients from seeking treatment. The authors illustrate how Piezocision™ combined with Invisalign® can be used in selected cases to successfully treat adults who would otherwise not pursue orthodontic treatment.

“ This case report illustrates how Piezocision™ (Piezotome®, SATELEC®, ACTEON®, France) combined with Invisalign® can be used in selected instances to satisfy the needs of esthetic-and time-conscious adult patient. This novel technique can be combined with different orthodontic treatment modalities to satisfy today's adult patient population. ”

RAPID TREATMENT OF CLASS II MALOCCLUSION WITH PIEZOCISION™: TWO CASE REPORTS

S. Dibart, J. Surmenian, JD. Sebaoun, L. Montesani

The International Journal of Periodontics & Restorative Dentistry, Vol. 30, N°5, Oct 2010

Abstract

An increasing number of adult patients are seeking orthodontic treatment to enhance their smile or their masticatory function. In this fast-paced and self-conscious society, time and esthetics have become increasingly important. One of the biggest challenges an adult orthodontic patient faces is the time spent wearing brackets. Over the years, several surgical techniques have been developed to address this issue and reduce overall treatment time. Although very effective, these techniques have proven to be quite invasive. A new, minimally invasive procedure (Piezocision™) is presented that combines microincisions and localized piezoelectric surgery to achieve similar results rapidly and with minimal trauma.

“ The successful and rapid treatment of two patients with angle Class II malocclusions is presented through use of Piezocision™ (with BS1, Piezotome®, SATELEC®, ACTEON®, France) minimally invasive procedure. This technique combines microincisions with selective tunneling that allows for hard and soft tissue grafting and piezoelectric incisions. This combination of buccal interproximal microincisions and localized piezoelectric corticotomies is able to create a significant amount of demineralization around teeth in the areas of tooth movement, making this a very attractive alternative to conventional and more aggressive techniques. The procedure strengthens the patient's periodontium while cutting down treatment times drastically (ideal for adult patients with time limitations). ”

PIEZOCISION™: A MINIMALLY INVASIVE, PERIODONTALLY ACCELERATED ORTHODONTIC TOOTH MOVEMENT PROCEDURE

S. Dibart, JD. Sebaoun, J. Surmenian
Compendium, Vol. 30, N°6, July-August 2009

Abstract

An increasing number of adult patients have been seeking orthodontic treatment, and a short treatment time has been a recurring request. To meet their expectations, a number of surgical techniques have been developed to accelerate orthodontic tooth movement. However, these have been found to be quite invasive, leading to low acceptance in patients and the dental community. The authors are introducing a new, minimally invasive procedure, combining microincisions with selective tunneling that allows for hard or soft tissue grafting and piezoelectric incisions. This novel approach is leading to short orthodontic treatment time, minimal discomfort, and great patient acceptance, as well as enhanced, or stronger, periodontium. Because of the added grafting (bone and/or soft tissue), the periodontium is much thicker buccally.

“ Because of its micrometric and selective cut, the piezoelectric knife is said to lead to safe and precise osteotomies without any osteonecrosis damage. The technique being proposed here demonstrated similar clinical outcome when compared with the classic decortication approach but has the added advantages of being quick (decreased chair time), minimally invasive, and less traumatic to the patient. It takes typically 1 hour to complete both arches vs 3 to 4 hours. This technique is quite versatile because it allows for soft-tissue grafting at the time of surgery to correct mucogingival defects if needed, as well as bone grafting in selected areas by using localized tunneling. ”

ACCELERATION OF ORTHODONTIC TOOTH MOVEMENT FOLLOWING SELECTIVE ALVEOLAR DECORTICATION: BIOLOGICAL RATIONALE AND OUTCOME OF AN INNOVATIVE TISSUE ENGINEERING TECHNIQUE

JD Sebaoun, J. Surmenian, DJ. Ferguson, S. Dibart
International Orthodontics, 6, 235-249, 2008

Key words

Selective alveolar decortication, Rapid treatment, Osteopenia, Corticotomy-assisted orthodontics.

Abstract

Following selective alveolar decortication as defined by the surgical scarring of the alveolar cortex, severe malocclusions can be orthodontically treated in six months. When combined with bone grafting, this technique also significantly expands the scope of treatment in resolving extreme dental arch crowding or borderline skeletal problems with stable clinical outcomes. The biology of rapid tooth movement after selective alveolar decortication involves a transient decrease in bone density thus creating a local environment of less resistance. Animal studies verify demineralization-remineralization (osteopenia) as the rationale for rapid orthodontics and it is surmised that the stability of orthodontic outcome is due to increased tissue turnover and increased cortical bone thickness due to the graft. With careful treatment planning and understanding of the biological rationale, the alveolar bone metabolism can be locally manipulated to achieve stable and rapid orthodontic results.

“ The healing response to the cortical bone injury can be exploited and manipulated clinically by moving teeth at the healing site. Doing so perpetuates the osteopenia (decreased bone density but not bone volume) and the augmentation grafting increases alveolar volume. Orthodontic treatment outcomes are more stable because of the high tissue turnover after surgery and the increased cortical bone thickness because of the grafting. The scope of tooth movement is at least doubles in most spatial dimensions if orthodontics is combined with decortication and grafting and treatment times are 3X to 4X times more rapid. ”

IMMEDIATE EXTRACTION PLACEMENT AND LOADING IN THE AESTHETIC ZONE

J. Kleiber

Implant Dentistry Today, January 2013

Aims and objectives:

The aim of this article is to demonstrate an approach for immediate implantation following atraumatic extraction in the aesthetic zone.

The reader will:

- Learn the three key factors for immediate placement and provisionalisation;
- See the protocol for achieving them;
- Understand the role of piezosurgery in aiding atraumatic extraction.

“ The piezosurgery unit used here was the Piezotome® 2 (SATELEC®, ACTEON®), with the specifically designed extraction tips. This unit has certain advantages over others as it has a light that allows clear vision of the periodontal ligament space and surrounding tissues. It also has an extremely wide range of power settings that allows it to adapt to the clinical situation by providing gentle luxation, or a more vigorous manipulation quickly and easily. ”

COMPARATIVE EVALUATION OF SURGICAL OUTCOME AFTER REMOVAL OF IMPACTED MANDIBULAR THIRD MOLARS USING A PIEZOTOME® OR A CONVENTIONAL HANDPIECE: A PROSPECTIVE STUDY

M. Goyal, K. Marya, A. Jhamb, S. Chawla, P.R. Sonoo, V. Singh, A. Aggarwal
British Journal of Oral and Maxillofacial Surgery, 50(6):556-61. September 2012

Keywords

Piezosurgery; Piezotome®; Third molar surgery; PoSSe scale.

Abstract

A new supragingival scaling technique associated with a fluorescent plaque disclosing unit for extraction of lower third molars. Our aim was to compare the use of a conventional rotary handpiece and a Piezosurgical unit for extraction of lower third molars. We studied 40 patients, who were allocated alternately to have the third molar removed with either the handpiece or the Piezosurgical unit. Pain, trismus, and oedema were evaluated at baseline and then postoperatively, together with paraesthesiae, on postoperative days 1, 3, 5, 7, and 15. Damage to surrounding tissue was checked on the same day whereas dry socket was evaluated from postoperative day 3 onwards. More patients complained of pain in the conventional group, they also required more analgesics, and they developed trismus more often than in the piezosurgery group. There was also significantly more postoperative swelling in the conventional group. Patients were also evaluated using the subjective Postoperative Symptom Severity (PoSSe) scale. Our results suggest that apart from some inherent limitations with the Piezotome®, it is a valuable alternative for extraction of third molars.

“ When we compared the overall outcome in the two groups, we found significantly less pain, trismus, and facial swelling and a better perception of the quality of life by the patients after third molar extraction using the Piezotome® (SATELEC®, ACTEON®). ”

ULTRASONIC PIEZOTOME® SURGERY: IS IT A BENEFIT FOR OUR PATIENTS AND DOES IT EXTEND SURGERY TIME? A RETROSPECTIVE COMPARATIVE STUDY ON THE REMOVAL OF 100 IMPACTED MANDIBULAR 3RD MOLAR

A. Troedhan, A. Kurrek, M. Wainwright
Open Journal of Stomatology, 2011

Keywords

Ultrasonic Surgery; Piezotome®; Rotating Instruments; Post Surgical Swelling; Post Surgical Pain; Impacted Mandibular Third Molars; Osteotomy.

Abstract

Aim of the study was to evaluate if there is a constant and significant reduction in traumaticity when massively traumatic oral surgical procedures such as the removal of third molars are conducted with only ultrasonic surgical devices (Piezotomes®) expressed in a reduction of postsurgical pain and swelling on the patient's side since such clinical experiences by the authors suggested this. Since oral surgeons criticize a higher time consumption for surgeries with Piezotomes® also the objective time consumption was evaluated and compared to the traditional methods.

Materials and Methods:

56 female and male patients were selected that already underwent a removal of an impacted third mandibular molar on one side with rotary instruments by bone destructive burring with a still persisting comparable third mandibular molar on the contralateral side complaining about recurrent pain episodes and were already documented for pain and swelling before. The ultrasonic surgical removal with the Piezotome® was conducted with a buccal osteotomy of the compacta lateral to the impacted third molar, preservation of the resected compacta in saline solution, removal of the third molar by single or multiple dentotomy and full anatomical restitution of the surgical site with the preserved buccal compacta. The swelling was documented by cephalometry 24/48/72 hours and 1 week post surgery, the pain index by the total consumption of ibuprofen-400 mg—tablets. Lesions of the mandible nerve were documented. Netto surgery time was taken from the first incision to the last suture of the procedure.

Results:

6 patients had to be excluded from evaluation due to incomplete post surgical follow up. A significant (***) decrease in pain and swelling of 50% was detected both for the parameters swelling and pain with Piezotome®-surgery. No lesions of the mandible nerve were detected with Piezotome® surgery whereas surgery with rotary instruments resulted in 16% hypesthesia at least up to one week. Although netto surgery time was approximately 50% longer when done with the Piezotome® at the beginning the time consumption normalized with the growing experience of the surgeons back to the time schedule when surgery was performed with rotary instruments revealing no significant differences (-, $p < 0.73$).

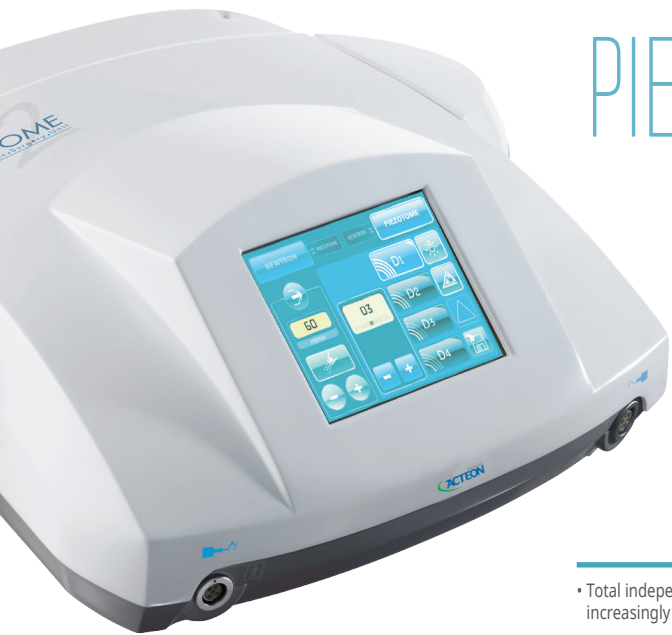Conclusions:

The results of this retrospective study suggest that Piezotome®-surgery is superior in atraumaticity and soft-tissue safety compared to traditional procedures with burs and grants the patients significantly less post surgical pain and swelling. Although, as it is with all new surgical tools and protocols, surgery time is longer at the beginning when purely working with ultrasonic surgical devices time consumption reduces to normal values after a learning curve.

“ Piezotome®-surgery is superior in atraumaticity and soft-tissue safety compared to traditional procedures with burs and grants the patients significantly less post surgical pain and swelling. No lesions of the mandible nerve were detected with Piezotome® surgery whereas surgery with rotary instruments resulted in 16% hypesthesia at least up to one week. Ultrasonic surgical devices time consumption reduces to normal values after a learning curve showing no significant time difference to procedures with rotary instruments. ”

I AM
POWERFUL*

I AM
POWERFUL*



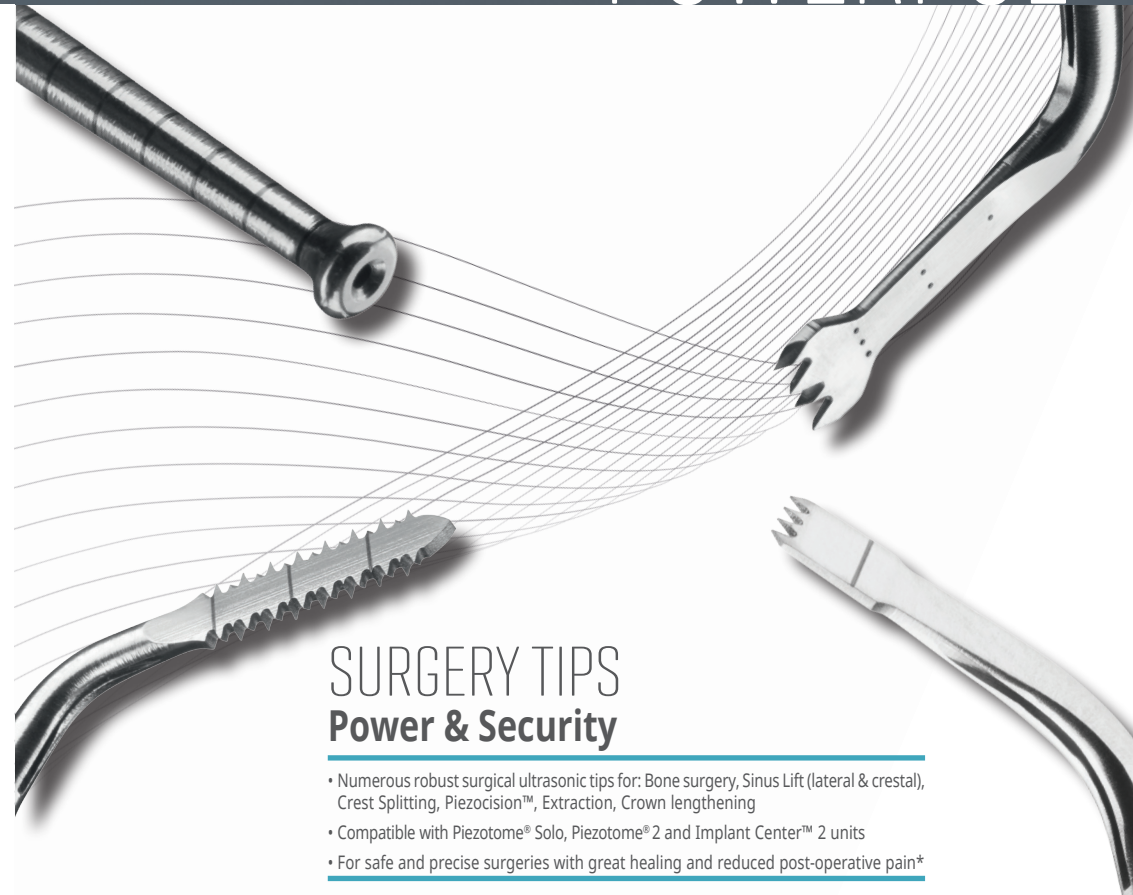PIEZOTOME 2

ACTEON®'s ultrasonic expertise in dental and surgical treatments

- Total independence with innovative, broad and robust tip range for increasingly diverse clinical areas
- Boosted performances with 6 ceramic rings Piezotome® LED handpiece
- Highly reliable thanks to the Newtron® technology providing preservation, efficacy and comfort



Français
* Je suis puissant



SURGERY TIPS Power & Security

- Numerous robust surgical ultrasonic tips for: Bone surgery, Sinus Lift (lateral & crestal), Crest Splitting, Piezocision™, Extraction, Crown lengthening
- Compatible with Piezotome® Solo, Piezotome® 2 and Implant Center™ 2 units
- For safe and precise surgeries with great healing and reduced post-operative pain*



Français
* Je suis puissant